

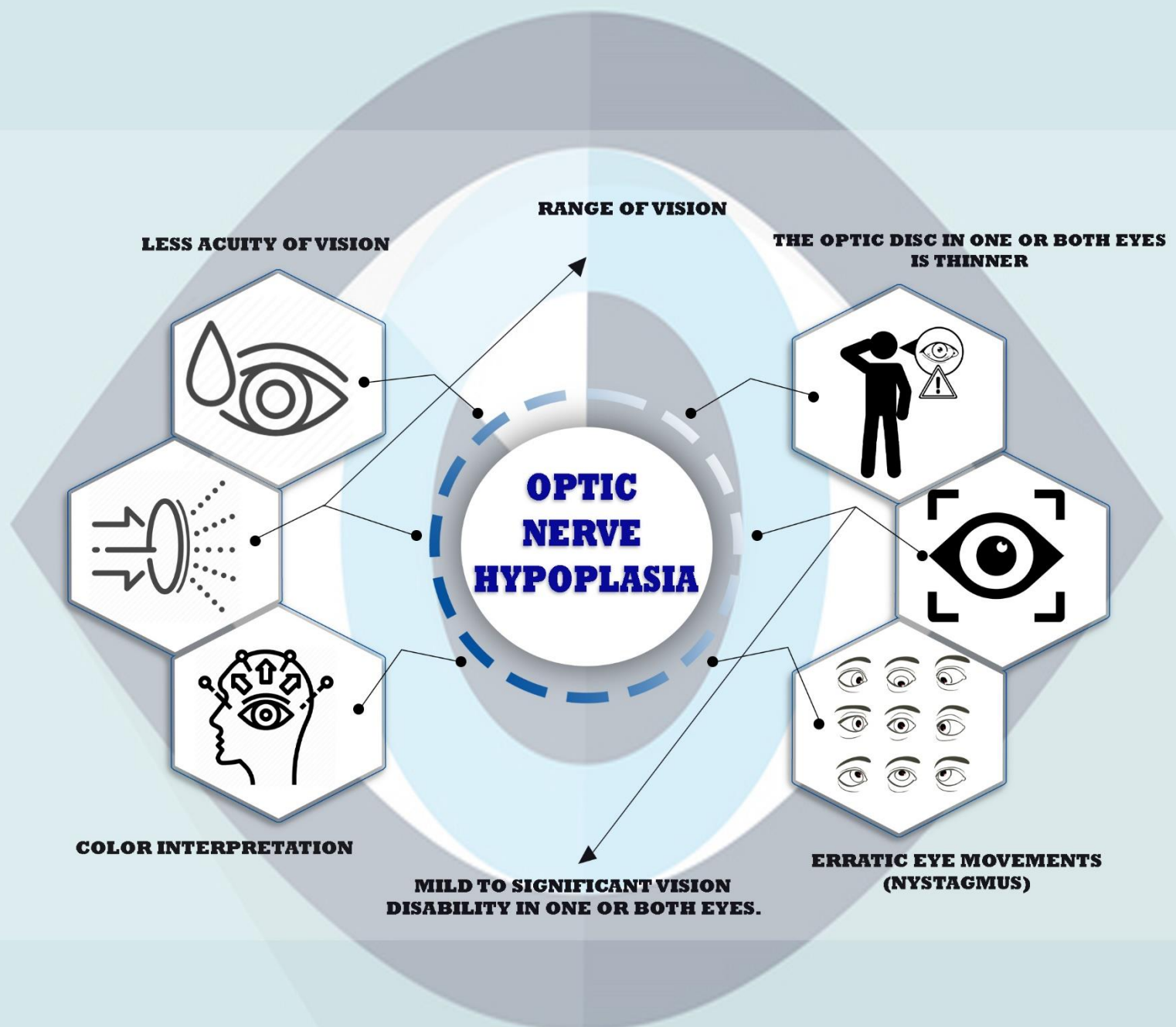


HAPPY OPTIC NERVE HYPOPLASIA PATIENTS

OVERVIEW

Optic nerve hypoplasia (ONH) befalls from the underdevelopment of the optic nerve, the sole purpose of which is to carry neuronal transmission from the retina in the eye to the brain

SOD also elicits other symptoms such as pituitary deficiency, autistic behaviors, epileptic seizures, etc

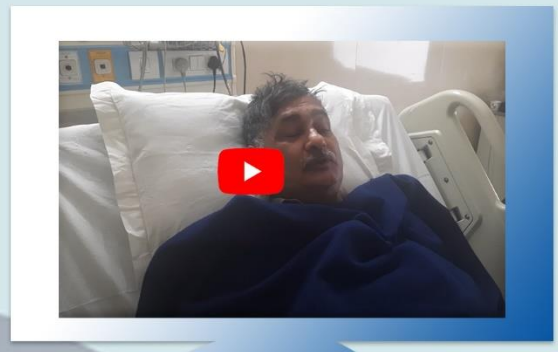

PATIENT VIDEO



Patient brother shares his experience after stem cell therapy for Toxic Optic Atrophy at SCCI

▶ <https://www.youtube.com/watch?v=kzw1oBo2SxY&list=PLELQLL6bv4tULmN4HuPCIsCMPAp6BWlio&index=2>



Patient with bilateral Optic Atrophy & Multiple Sclerosis shares his experience at SCCI| Stem Cells

▶ https://www.youtube.com/watch?v=wim_7qecYoE&list=PLELQLL6bv4tULmN4HuPCIsCMPAp6BWlio&index=8



Patient with Toxic Optic Atrophy shares his experience at SCCI| Toxic Optic Atrophy StemCell Therapy

▶ <https://www.youtube.com/watch?v=nZv40nQLILM&list=PLELQLL6bv4tULmN4HuPCIsCMPAp6BWlio&index=11>



Patient with Glaucoma & Optic Nerve atrophy shares his experience after stem cell therapy at SCCI

▶ <https://www.youtube.com/watch?v=ROzRzmuZ-YM&list=PLELQLL6bv4tULmN4HuPCIsCMPAp6BWlio&index=17>



PATIENT WITH MS WITH NEUROMYELITIS OPTICA (NMO) & AMP ONA. SHARES HER EXPERIENCE AT SCCI | STEM CELL

▶ <https://www.youtube.com/watch?v=QGCI0h1u3Ng&list=PLELQLL6bv4tULmN4HuPCIsCMPAp6BWlio&index=24>



Patient Brother with Toxic Optic Atrophy shares his experience at SCCI| Toxic Optic Atrophy StemCell

▶ https://www.youtube.com/watch?v=JGjrUWW_s8E

PATIENT VIDEO



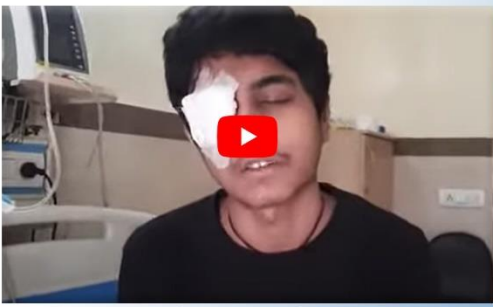Patient with Bilateral Toxic Optic Neuropathy shares her experience at SCCI Stem Cell Therapy

▶ <https://www.youtube.com/watch?v=dBYhoes6roY&list=PLELQLL6bv4tULmN4HuPCIsCMPAp6BWlio&index=22>



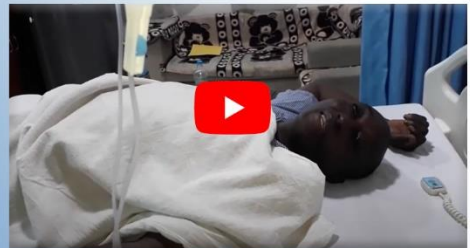Patient with bilateral Optic Atrophy & Multiple Sclerosis shares his experience at SCCI Stem Cells

▶ https://www.youtube.com/watch?v=wim_7qecYoE&list=PLELQLL6bv4tULmN4HuPCIsCMPAp6BWlio&index=8



Patient with optic neuropathy shares his experience at SCCI stem cell therapy for optic neuropathy

▶ <https://www.youtube.com/watch?v=PI7O-WmY2qk&list=PLELQLL6bv4tULmN4HuPCIsCMPAp6BWlio&index=12>



Patient with Glaucoma & Optic Nerve atrophy shares his experience after stem cell therapy at SCCI

▶ <https://www.youtube.com/watch?v=iJEV5dcxNFY&list=PLELQLL6bv4tULmN4HuPCIsCMPAp6BWlio&index=19>



PATIENT ATTENDANT SHARES HIS EXPERIENCE AFTER STEM CELL THERAPY FOR OPTIC NEUROPATHY AT SCCI

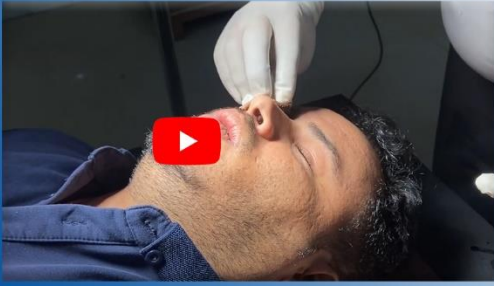▶ <https://www.youtube.com/watch?v=s9ucWWX-2N0&list=PLELQLL6bv4tULmN4HuPCIsCMPAp6BWlio&index=16>



Patient from Yeman for Toxic Optic Nerve Atrophy Treatment Retrobulbar during Retro Bulbar Injection

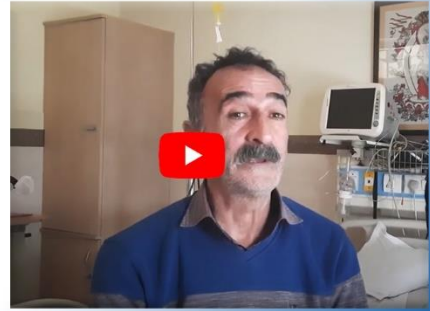▶ <https://www.youtube.com/watch?v=00Nua4Vz0vA&list=PLELQLL6bv4tULmN4HuPCIsCMPAp6BWlio&index=27>

PATIENT VIDEO



Patient from Yeman for Toxic Optic Nerve Atrophy Treatment Retrobulbar during Retro Bulbar Injection

▶ <https://www.youtube.com/watch?v=00Nua4Vz0vA>



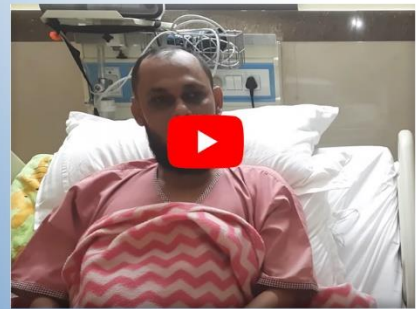Patient with Toxic Optic Atrophy shares his experience at SCCI| Toxic Optic Atrophy StemCell Therapy

▶ <https://www.youtube.com/watch?v=liStT1WGdgw>



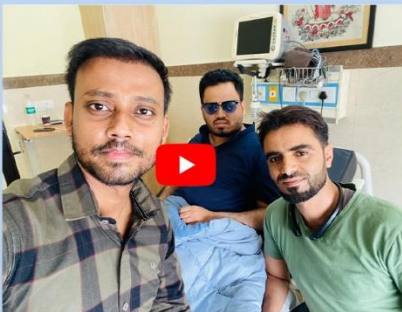Patient with Toxic Optic Atrophy shares his experience at SCCI| Toxic Optic Atrophy StemCell Therapy

▶ https://www.youtube.com/watch?v=Z-TZ_AhL_iM



Patient with Toxic Optic Atrophy shares his experience at SCCI| Toxic Optic Atrophy StemCell Therapy

▶ <https://www.youtube.com/watch?v=dRuEYgvk1HU&t=34s>



EMAD ABDU MOHAMMED CAME FROM YEMEN FOR TOXIC OPTIC NERVE ATROPHY TREATMENT SCCI

▶ <https://www.youtube.com/watch?v=FornTfcsKGA&t=14s>



Patient attendant with Toxic Optic Atrophy shares his experience at SCCI | Toxic Optic Atrophy

▶ <https://www.youtube.com/watch?v=jQjGBkhqc-Y>

PATIENT VIDEO



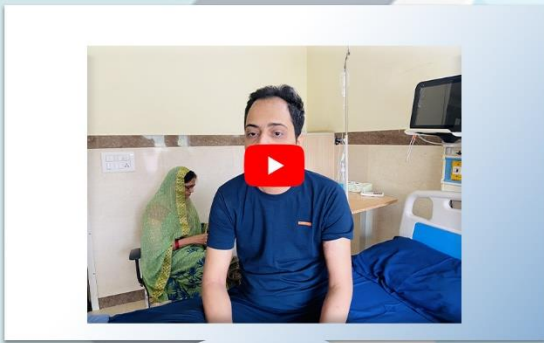
R Rahul Krishnan came from Kerela for Post Traumatic Optic Nerve Atrophy Treatment SCCI

 <https://www.youtube.com/watch?v=nchXyc1uluo>



Patient with bilateral Optic Atrophy shares his experience at SCCI| Optic Atrophy Stem Cell Therapy

 <https://www.youtube.com/watch?v=6tytuluZ9nE>



Patient shares his experience after stem cell therapy for Optic atrophy at SCCI| Stem cell Therapy

 <https://www.youtube.com/watch?v=bLeV9DMRRcY>



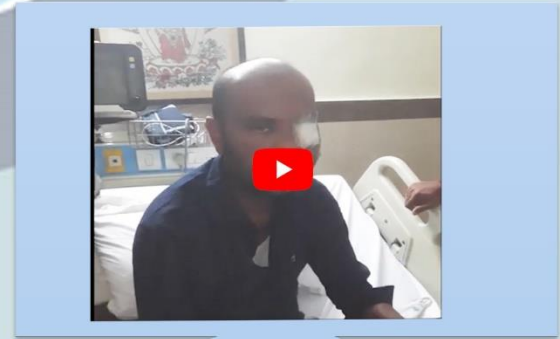Patient father shares his experience after stem cell therapy for Optic atrophy at SCCI| Stem cells

 <https://www.youtube.com/watch?v=Nuxccu4PSd4>



PATIENT ATTENDANT SHARES HIS EXPERIENCE AFTER STEM CELL THERAPY FOR OPTIC ATROPHY AT SCCI

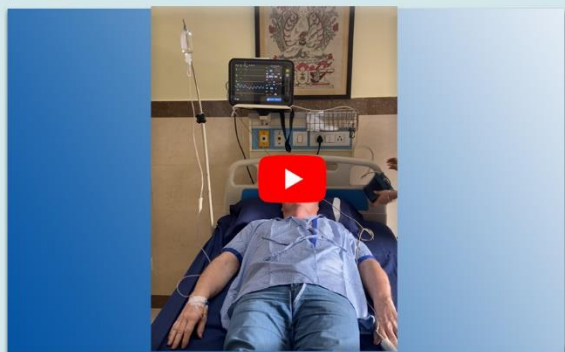 <https://www.youtube.com/watch?v=SIJCQILIGBA>



Patient with Toxic Optic Atrophy shares his experience at SCCI| Toxic Optic Atrophy StemCell Therapy


 <https://www.youtube.com/watch?v=YQ2WrLIX8sU&t=5s>

PATIENT VIDEO



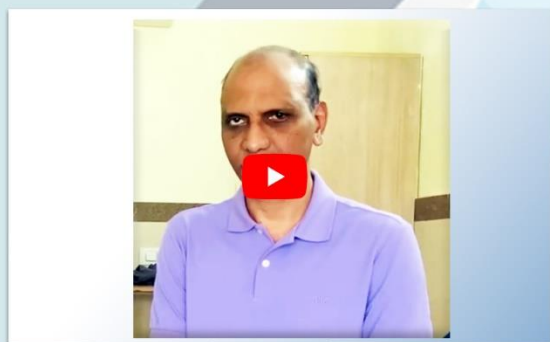
THE PATIENT COME FROM SWITZERLAND, REGENERATIVE MEDICINE THROUGH IV INFUSION FOR RP

▶ <https://www.youtube.com/watch?v=qa1IHgQKXd4>



Patient with Retinitis Pigmentosa shares his experience at SCCI| RP treatment| stem cell therapy

▶ <https://www.youtube.com/watch?v=wosj0hz-ka4&t=1s>



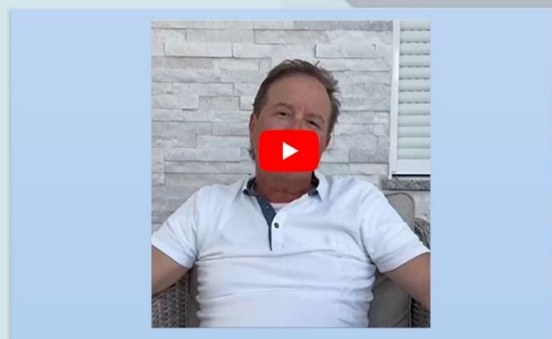The Patient from Thailand Shares His Experience After Stem Cell Therapy for Retinitis Pigmentosa

▶ <https://www.youtube.com/watch?v=EVRkm9vtNjQ>



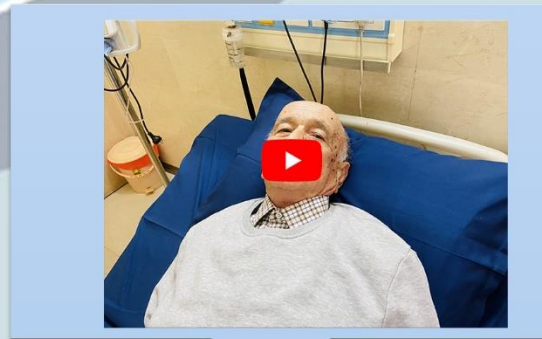Best Treatment For Retinitis Pigmentosa | Stem Cell Therapy | Exosome | Stem Cell Center For RP |

▶ https://www.youtube.com/watch?v=NPEa3c4_-5E



THE PATIENT FROM SWITZERLAND, REGENERATIVE MEDICINE THROUGH IV FOR RETINITIS PIGMENTOSA | Stem Cell

▶ <https://www.youtube.com/watch?v=YihTcTYAIEg>

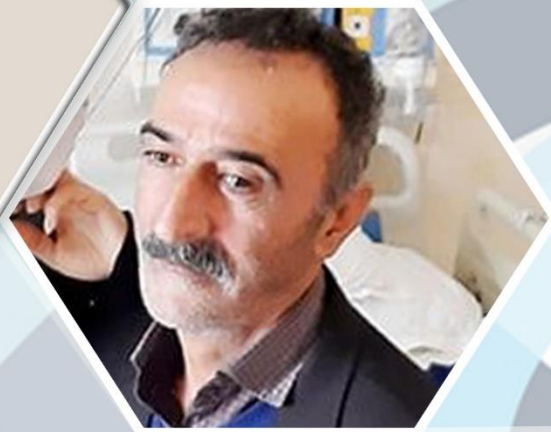

DIET CONSULTATION FOR AGE-RELATED MACULAR DEGENERATION, THE PATIENT FROM UZBEKISTAN | STEM CELL |

▶ [DIET CONSULTATION FOR AGE-RELATED MACULAR DEGENERATION, THE PATIENT FROM UZBEKISTAN | STEM CELL |](#)



Stem Cell Care
India

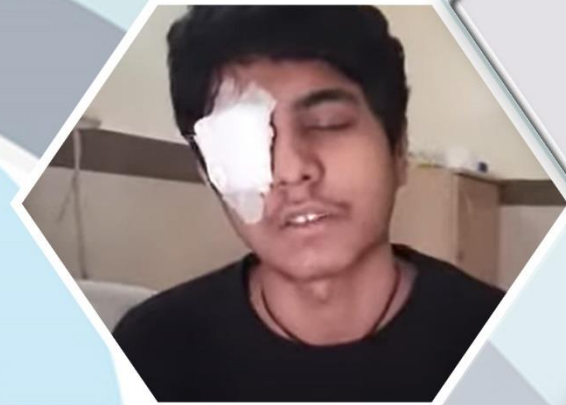

EYE DISORDER PATIENTS GALLERY

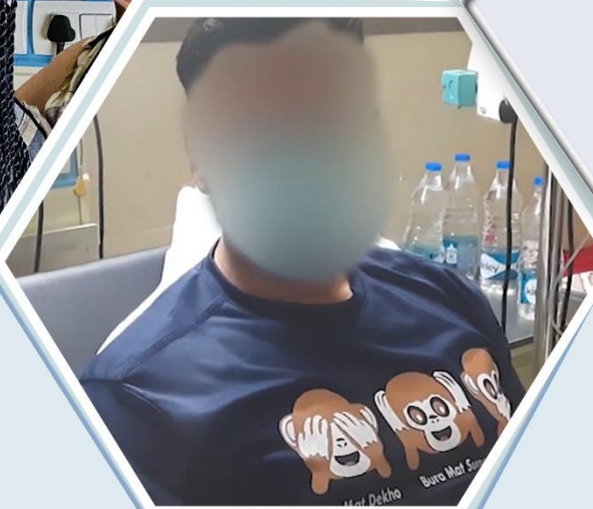
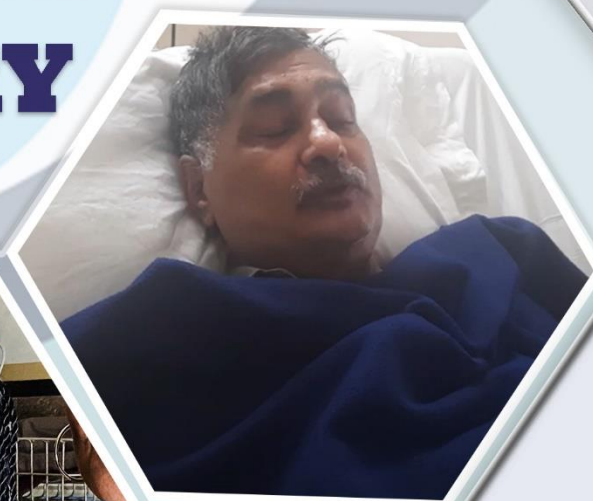


Stem Cell Care
India



EYE DISORDER PATIENTS GALLERY



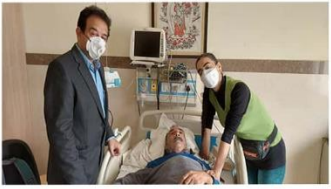HAPPY PATIENTS

HAPPY PATIENTS



FAZLOLAH MOTAGHI

came from Iran for Optic Neuropathy Treatment



Optic neuropathy is a common form of vision loss that ophthalmologists see. The diagnosis is made for research reasons only. The aetiology of optic neuropathy can also be traced back in time. Quick initiation is associated with demyelinating, inflammatory, ischemic, and traumatic causes. A progressive path demonstrates compressive, toxic/nutritional, and hereditary factors.

Typical clinical signs of optic neuropathy include visual field defect, dyschromatopsia, and compromised papillary reaction. There are ancillary inquiries that can assist in the diagnosis of optic neuropathy. Visual field control, whether manual kinetic or automated static perimetry, is critical in diagnosis.

Neuro-imaging of the brain and orbit is critical in some optic neuropathies, such as demyelinating and compressing. Multifocal evoked vision potentials and tomography of optic coherence are two recent advancements in the evaluation of optic neuropathies.

People suffering from this disease have undergone the best stem cell therapies from Stem Cell Care India, and their symptoms have changed as a result of the stem cell treatment.

www.stemcellcareindia.com
info@stemcellcareindia.com
+91 8743024344



MR MD ANOWER HOSSAIN

Came from Bangladesh for for Bilateral Toxic Optic Neuropathy Treatment



PATIENT STORY

I have been battling disability for two years and nine months. For the first time I visited Bangladesh hospital for treatment, consultation went fine but no solution no progress. Then I got to know about stem cell treatment and started to Google more about it any hospital nearby.

My research landed me to for Stem Cell Care India and the staff got in touch with us, they told us that the treatment is possible so, we came here. They asked me to fill the patient information and provide all the documents related to my condition.

During my treatment here I can assure it went really well, it was a very cooperative environment. I'm satisfied with the treatment.



EMAD ABDU MOHAMMED

Came from Yeman for Toxic Optic Nerve Atrophy Treatment of his brother.



PATIENT STORY

My name is Emad Abdu, and I came from Yamen for toxic optic nerve atrophy treatment of my cousin at SCCI. We travelled to many places but didn't find anybody to treat this problem. Lastly, we came here and book down the procedure for stem cells. At SCCI, my experience is amazing, and I also recommend people with the same problem come here for treatment.

www.stemcellcareindia.com
info@stemcellcareindia.com
+91 8743024344

HAPPY PATIENTS

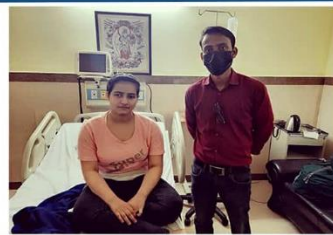

AHEMAD MUSAID SALEH ALSHAABI came from Yeman for Toxic Optic Nerve Atrophy Treatment

I was diagnosed with a sudden loss of vision in 2018 because of methanol poisoning. We tried several treatments but didn't get any improvement. At last, we wished to go through stem cell treatment that came to me at SCCI. I have good experience with the hospital and I'm also feeling improvement in my problem.

PATIENT STORY

www.stemcellcareindia.com
info@stemcellcareindia.com
+91 8743024344



RIYA SARKAR

came from Kolkata for Optic Nerve Atrophy

Hi, I am Riya Sarkar. I have come here from Kolkata. In 2015, I suffered from tuberculosis meningitis. After that, I lost the vision of my eyes. In order to get an apt yet effective treatment, I consulted a lot of doctors at a lot of hospitals like Vimhans, CMC, etc. But, everywhere, the doctors told me that my condition is incurable and there isn't any treatment for my condition. After that, we searched online and got to know about the miracles of stem cell treatment. In India, the best is Stem Cell Care India. I got admitted in hospital via Stem Cell Care India on 7th March. On 8th March, I was injected with stem cells injection. After that, doctor said that he is hoping that I will get better and will be able to see the world again as I can get back my lost vision. Initially, I was very nervous and scared before taking the stem cell treatment. However, doctors at SCCI treated me so well. They carried out my treatment so well and with utmost carefulness. I am really happy after receiving treatment from SCCI.

PATIENT STORY



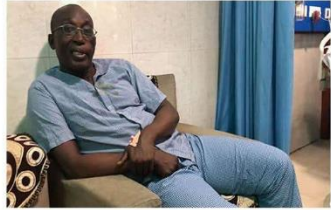R RAHUL KRISHNAN came from Kerela for Post Traumatic Optic Nerve Atrophy Treatment

I had a history of loss of vision after an accident in 2019. I am taking conservative medical treatment and wish to undergo stem cell therapy for the problem that has brought me to SCCI. I have very good experience with this hospital. Their staff is also very friendly and professional. I am very glad that I come across them.

PATIENT STORY

www.stemcellcareindia.com
info@stemcellcareindia.com
+91 8743024344

HAPPY PATIENTS



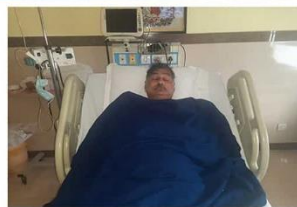PROFESSOR NICHOLAS

Came from Ghana, Africa for Vision Loss Treatment

Hi, I am Professor Nicholas from Ghana. I am a professor of Statistics. I came to India for availing the stem cell treatment for vision loss via Stem Cell Care India. Few years back, I had stated encountering that my vision was deteriorating, both in terms of quality and sharpness. For getting the treatment, last year I travelled to China, where I was kept in the hospital for around 16 days and was charged a lot of money as well. However, I didn't attain any relief. After this, I stated searching and exploring more about stem cell treatment. After my research, I decided to opt for Stem Cell Care India's stem cell treatment for eyes in India. I contacted the hospital and they helped me a lot in imparting all the important information about the treatment to me. I realized that the cost of treatment in India is very much less to what I had to pay in other nations. When I came to India, the treatment started and I was given vitamins and other medications. Stem cell treatment that I undergone was very simple and I got recovered very speedily. I experienced a lot of improvement in my eyesight. Also, the staff of the hospital is also very friendly, cooperative and caring.

PATIENT STORY

www.stemcellcareindia.com
info@stemcellcareindia.com
+91 8743024344

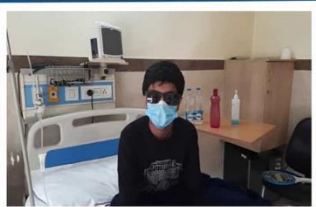

VIJAY KUMAR

came from Punjab for Bilateral Optic Atrophy & Multiple Sclerosis

Hi, I am Vijay Kumar and I live in Hoshiarpur, Punjab. 3 months back, there was some problem that occurred in my eyes. Because of that problem, I lost my vision. After trying a lot of other treatments, I finally decided to undergo stem cell treatment. I researched about Stem Cell Care India. Then, I came to Delhi and contacted my known people in Faridabad for proper diagnosis. After the stem cell therapy was given to me, I am feeling a lot better. After the 2nd day of stem cell injections, I am feeling there is a lot of improvement in my condition. Thanks to the whole team of Stem Cell Care India. They have taken really good care of me here. I am hopeful that God will do much better for me ahead in life.

PATIENT STORY



KUNAL MONDAL

came from Kolkata for Optic Nerve Atrophy Treatment

Hi, I am Kunal's father Mr. Vishwajeet Mondal. I came to Delhi from Kolkata. My son is suffering from Optic Neuropathy from past 2 years. His treatment course is going on during which he developed some eye problems. His vision in both the eyes has reduced significantly. We were really bothered for him and took him to several clinics for treatment. But there were not much improvement in his condition. Then, we came to Delhi and got to know about stem cell treatment for optic atrophy from Stem Cell Care India. The doctors at Stem Cell Care India promised us to treat my son's eyes perfectly. So, as per their promise, they have been treating my son with great care and precision via stem cell therapy. Stem cells injections have been given to my son and doctors also gave him multi-vitamins tablets. we will be leaving for Kolkata on 5th October 2020 and we are hopeful that this treatment works really well on him and we are quite appreciative of the staff of Stem Cell Care India.

PATIENT STORY

www.stemcellcareindia.com
info@stemcellcareindia.com
+91 8743024344

HAPPY PATIENTS



SHAUNA FULLARD

came USA for MS with Neuromyelitis Optica & amp ONA Treatment

My name is Shauna Fullard and I have come from America to take stem cell treatment for treating Neuromyelitis Optica & amp ONA disorder. Earlier, I took chemotherapy and several other treatments, but I didn't get any benefit. After taking stem cell treatment, my condition is stable. I'm satisfied with this effective treatment.

PATIENT STORY

www.stemcellcareindia.com
info@stemcellcareindia.com
+91 8743024344



HAPPY PATIENTS



MS. DIVYA

came from Adhara Pradesh for Optic Neuropathy

Optic neuropathy is a common form of vision loss that ophthalmologists see. The diagnosis is made for research reasons only. The aetiology of optic neuropathy can also be traced back in time. Quick initiation is associated with demyelinating, inflammatory, ischemic, and traumatic causes. A progressive path demonstrates compressive, toxic/nutritional, and hereditary factors.

Typical clinical signs of optic neuropathy include visual field defect, dyschromatopsia and compromised papillary reaction. There are ancillary inquiries that can assist in the diagnosis of optic neuropathy. Visual field control, whether manual kinetic or automated static perimetry, is critical in diagnosis.

Neuro-imaging of the brain and orbit is critical in some optic neuropathies, such as demyelinating and compressing. Multifocal evoked vision potentials and tomography of optic coherence are two recent advancements in the evaluation of optic neuropathies.

People suffering from this disease have undergone the best stem cell therapies from Stem Cell Care India, and their symptoms have changed as a result of the stem cell treatment.



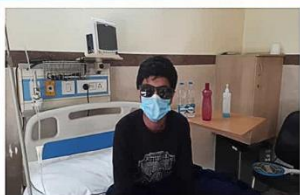KUNAL MONDAL

came from Kolkata for Optic Nerve Atrophy Treatment

Hi, I am Kunal's father Mr. Vishwajeet Mondal. I came to Delhi from Kolkata. My son is suffering from Optic Neuropathy from past 2 years. His treatment course is going on during which he developed some eye problems. His vision in both the eyes has reduced significantly. We were really bothered for him and took him to several clinics for treatment. But there were not much improvement in his condition. Then, we came to Delhi and got to know about stem cell treatment for optic atrophy from Stem Cell Care India. The doctors at Stem Cell Care India promised us to treat my son's eyes perfectly. So, as per their promise, they have been treating my son with great care and precision via stem cell therapy. Stem cells injections have been given to my son and doctors also gave him multi-vitamins tablets. we will be leaving for Kolkata on 5th October 2020 and we are hopeful that this treatment works really well on him and we are quite appreciative of the staff of Stem Cell Care India.

PATIENT STORY

www.stemcellcareindia.com
info@stemcellcareindia.com
+91 8743024344





Iqbal Hossain Sarker

2 reviews · 3 photos

★★★★★ a year ago

We came here for stem cell treatment for optic nerve damaged. Already we got it. Hope it will be better for us what we want. Their treatment procedure and hospitality very wonderful and helpful. We are satisfied about their whole treatment procedure. I hope they are doing well. All the best.



2

Response from the owner a year ago

Thank you so much. Hope you get to feeling better soon

Stem Cell Care India



Ram Singh

2 reviews

★★★★★ 3 years ago

I am thankful to stem cell care India for best service for optic nerve. Doctor staff and stem cell team member are very experienced and Coprative. Thanks



1

Response from the owner 3 years ago

Thank You



Aniket Kumar

5 reviews

★★★★★ 5 years ago

A big thank to Stem Cell Care India team, now I my uncle is absolutely fine after getting Optic Nerve Atrophy Treatment from your center.



4

Response from the owner a year ago

Thank you for the feedback and wish you a healthy life. Stem Cell Care India



radha Krishnan

1 review

★★★★★ 6 months ago

Very good experience and caring of the doctors also very good, I came for optic nerve damage treatment. I have take treatment 19 of June to 21st of June.



1

Response from the owner 6 months ago

Thank you for your feedback
Stem Cell CARE INDIA



Doris Fultang

1 review

★★★★★ 9 months ago

I came for treatment of my optic nerve problems, very happy with the treatment. Treatment went successfully. Great job



Response from the owner 9 months ago

Thank you for your feedback

Thank you for your feedback ... [More](#)



bachala veeraswamy

1 review

★★★★★ 8 months ago

When I was 17 years old I observed that my vision was decreasing gradually because of optic nerve athropy. when I was 21 I had stem cell therapy treatment after that I have seen alot of improvement in my vision. Thank you Stem cell care india.



Response from the owner 11 months ago

Thank you for your feedback



Rekha Rajput

1 review

★★★★★ 3 years ago

Hi stem cell team, i am giving my feedback after 5.3 months of my treatment. So i had taken stem cell for optic nerve atrophy. Currently i am 26 years old, Before the treatment i couldn't see my text messages, couldn't drive car or bike. Sometime feel pain in my eyes etc. But after 40 days i feel my pain was gone, and now i am able to see my messages, and i can see almost everything around 20 to 30 feet. Sometime i drive bike with my friends. So i am happy with my treatment. And happy with my result. 🙏 Tc, God bless you.



Response from the owner 2 years ago

Thank You very much and wishing you a happy & healthy life.



Puneeth Kumar N

2 reviews

★★★★★ a year ago

We went through Stem Cell Therapy for my co-brother for his optic nerve issue which was impacted due to black fungus. Everything went through fine, everyone was very co-operative. Special Thanks to Adhil for co-operation and Dr Manoj for all the help.

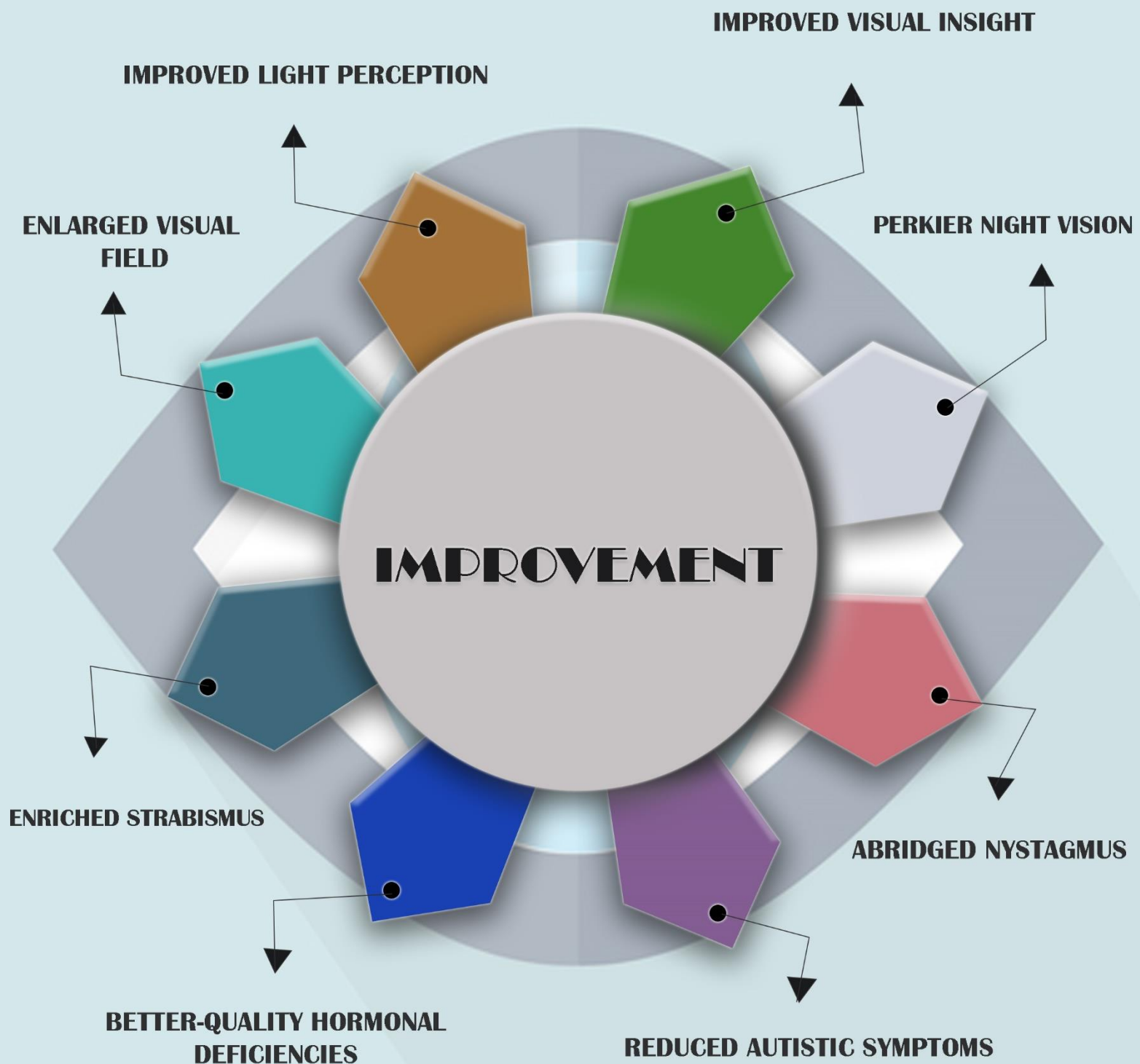


Response from the owner a year ago

Thank you for your feedback

Stem cell care India

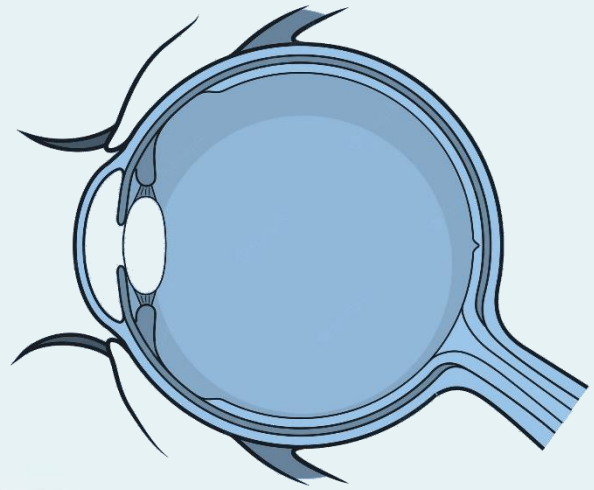
OUTCOME OPTIC NERVE HYPOPLASIA PATIENTS



Sadie

16 years, Texas, 2020

Hi, I am George Buyers, father of Sadie Buyers. My daughter has optic nerve hypoplasia, and for the past several years, we have been looking for an effective and safe treatment method for my kid. But every time, we only get rejection. Then one of my close friends told me about stem cell therapy. After lots of research and searching online, we learned about SCCI as they for this treatment via stem cells for multiple disorders, including my child's problem. She's been getting treatment for her optic nerve hypoplasia through Stem Cells. The treatment has been working well. Her vision is improving. We're very happy with the results. Thanks to the whole team of SCCI, because of you and your staff, we can observe good improvements in Sadie's vision has improved.



Mohinder

12 years, Punjab, 2022

My kid had this symptom that he would move his pupils incessantly and was also struggling with his motor abilities. I saw these symptoms emerging early on and started seeking medical help. After a fair bit of medical supervision, it was revealed that my son had optic nerve hypoplasia. Motivated to seek a cure, I researched over the internet what could help my son. It was then that I got to know about Stem cell Care in India. I was skeptical about Stem Cell Therapy helping my son's problems, but Stem Cell Care India promised results. Motivated by their trust in their therapies, we booked our appointments and came to India. After coming here, all our treatment was done according to our comfort. My son was not troubled in the least. After the treatment, we were kept to ensure there were no issues, and after that, we were deemed free. On returning, my son's motor abilities, as well as vision, have shown signs of improvement now. He can recognize shades and colors. In case you see similar symptoms seek medical help immediately without any delay.

Jaysingh

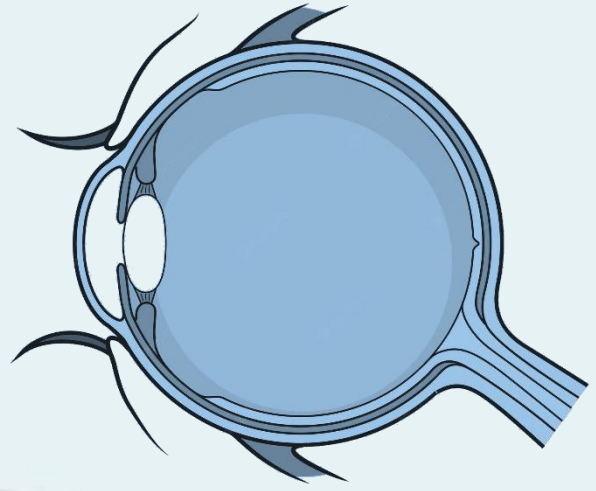
10 years, Patna, 2021

I was looking for a stem cell treatment for my baby, and I found this. It's effective and affordable, and the results are outstanding. After my treatment, I was able to experience better vision capabilities, and her condition improved massively. This is one of the best treatments for optic nerve hypoplasia that I've encountered, and I highly recommend it!

Belli

22 years, UK, 2022

Belli lost her sight in a matter of weeks in 2014 because of a severe case of optic neuritis – inflammation of an optic nerve that causes gradually blurry vision as the nerve could no longer interconnect with the brain. Until recently, dark shadows were the solitary thing she could make out, and she used a stick and numerous technological devices to help her move around. After undergoing stem cell therapy at SCCI, in which stem cells extracted from bone marrow in her hip were injected into a diverse area in each eye, she progressively recuperated some of her sight. She can now read menus and street signs, get around without her stick, and have seen her husband's face for the first time in 4 years.



John's Daughter

9 years, Boston, 2022

Hello, I am John Boswell from Boston, Texas; my kid showcased signs of Optic Nerve Hypoplasia, and we were scared for his vision loss. We wanted to seek a way out and start therapy for his eyes soon. Motivated to seek a complete cure, we were ready to try out any possible way out of the problem. While seeking such therapies, we learned about Stem Cell Care India and communicated with them regarding the treatment. They told us that their Stem Cell Therapy could help our kid and bring betterment to his vision. Motivated to try this therapy, we booked our appointments and came to India. Our treatment was done with the utmost care, and our kid was given the best care possible. After the treatment, we saw improvements in the symptoms. The therapy can help in rehabilitation and minimize the inflammation of cells in the eye, according to Stem Cell Care India, and I guess that's how they helped my son

Katie

4 years, USA, 2021

Katie is a 4 year old kid and she traveled to India with her parents so as to get stem cell treatment for optic nerve hypoplasia. Katie was first treated with stem cells in April of 2018 via SCCI. After her first treatment she started to see light and distinguish colors. With both eyes, she was also able to read and identify the colors of a green sign some 30 feet away. These improvements are not the first for Katie, and the family is undoubtedly hoping they are not the last.

PATIENT TESTIMONIALS

PATIENT NAME	AGE	DISORDER	COUNTRY	YEAR OF TREATMENT	FOLLOW-UP FEEDBACK
Ejaz Khan	45	Sports Injury	Afghanistan	2017	Shakes in the hands gone. Able to get out of the wheelchair.
Berley	6	Autism	Canada	2018	Speech and cognitive abilities improved. Balance amended while sitting.
Justin	32	Muscular dystrophy	Brazil	2017	Balance and feet strength improved. Was able to get out of wheelchair unaided.
Mohd. Kasim	72	Type 2 Diabetes	Kuwait	2019	100 % bladder control was there and patient's sugar levels were under control.
Wasim Jafar	39	Motor Neuron Disease	Ghana	2020	Muscle strength improved. Able to live a better and healthier life than before.
Kevin	12	Ataxia	USA	2020	Walking was improved to a great extent. Patient was able to balance himself better.
Jim Mark	29	Liver Cirrhosis	Lebanon	2019	The patient's liver function improved and is able to eat food in a better way.
Rajesh Batra	41	Optic nerve atrophy	India	2018	Was able to see and detect light better and the eyesight improved a lot.
Kelly	33	Retinitis Pigmentosa	Australia	2020	After the treatment, visual field test results were better. Field of view and night vision also improved.
Kristeen	37	Macular Degeneration	Taiwan	2019	Day & night vision became better with improved vision for objects & light.
Marie Bella	45	ILD	USA	2017	Patient recovered from the disease in a short span of time and is now living a better life.
Tony Joseph	54	Muscular Dystrophy	USA	2017	The patient's condition improved with regenerative medicine and physiotherapy both combined.
Ram Manohar	62	Optic neuritis	India	2017	Improved bilaterally in vision sharpness, visual field and is able to see far off things better now.
Mohd. Kadar	41	Muscular Atrophy	Qatar	2018	Enhancements in awareness, responsiveness and Better sensory stimulation.
Fendi Morrson	78	Anti-ageing	UK	2019	The patient was able to get rid of wrinkles and the skin became supple and younger than before.
Valson	67	Osteoarthritis	Indonesia	2020	Is now able to use the staircase without the need for handrail. Walking and gait has become much better.
Zachary	17	Friedrich's Ataxia	Canada	2015	Able to stand up, bend over and touch the floor for the first time in 3 years.

PATIENT TESTIMONIALS

PATIENT NAME	AGE	DISORDER	COUNTRY	YEAR OF TREATMENT	FOLLOW-UP FEEDBACK
Mark Morrison	58	Type 1 Diabetes	Canada	2017	Blood glucose levels were brought under control and foot ulcer also got cured.
Jordan	72	Heart disease	Germany	2018	Heart's ejection reaction improved a lot. Was able to live a healthier life after the treatment.
Pranjal Saxena	6	Cerebral palsy	India	2018	General muscle strength improved and considerable betterment in mobility and coordination.
Jospeh	46	Brain injury	Germany	2017	Much better results of improvement in awareness, responsiveness and sensations.
Ahmed Aksar	38	Multiple Sclerosis	Pakistan	2019	After treatment, the patient was able to walk at normal pace up to few kms.
Ashley	34	Ataxia	UK	2018	Able to stand up, bend down and touch the floor with ease and smoothness.
Oscar	42	ALS	USA	2020	Breathing and swallowing function improved greatly.
Zubina	51	CKD	Afghanistan	2017	Was able to survive without kidney transplant successfully.
Carl Smith	61	Rheumatoid arthritis	Germany	2018	Was able to use the staircase after a long time of 4 years. Pain in the knees also subsided.
David Paul	44	Spinal cord injury	Scotland	2019	Balance improved a lot while sitting. The patient is able to walk and stand in a much stable way.
Shehzad Ali	4	Autism	India	2017	Speech became clear and socially more affable. Balance and mobility also improved.
Sri Rangnath	45	Multiple sclerosis	Hungary	2018	Increased muscle strength was seen. The patient was able to sit and stand for long after the treatment.
Natalie	32	Glaucoma	Australia	2020	Was able to see objects at a distance in a better way after the treatment. Eyesight also improved.
Kathrine	16	Ataxia	England	2019	Balance of the body improved and is now able to walk properly without any support.
Thomas Clark	44	Retinopathy	South Africa	2017	Vision was improved significantly and the patient was able to see things in a better way.
Preetpal Singh	58	Osteoarthritis	USA	2018	Balance improved significantly and there was increased sensation in legs was seen.

PATIENT TESTIMONIALS


PATIENT NAME	AGE	DISORDER	COUNTRY	YEAR OF TREATMENT	FOLLOW-UP FEEDBACK
Jessica Kukreja	42	Traumatic brain injury	USA	2017	Tremors in the legs decreased with time and there was better stability in the legs.
Amy Jackson	3	Cerebral Palsy	Argentina	2020	Vivid increase in appetite and motor abilities also improved to a great extent.
Smith Bross	24	Spinal Cord Injury	Australia	2019	There were some amazing improvements observed after the treatment and the patient was able to walk better.
Rakesh Kumar	32	Duchenne Muscular Dystrophy	India	2015	Able to extend his limbs fully.
Jim Vishoot	35	Traumatic Brain Injury	USA	2015	Tension reduced in facial muscles. Strength in his legs increased.
Katharina Adler	35	Ataxia	Canada	2015	Walking improved considerably.
Andrew Ricci Wallace	3	Cerebral Palsy	Australia	2016	Stopped choking while drinking and the gastric emptying problem had improved and could eat food more than just mushy consistency.
Mr. Yusuf	32	Multiple Sclerosis	Nigeria	2015	Better balance, no double vision and improved sensation on her right side of the face.
Parul Dev	8	Cerebral Palsy	USA	2015	Gained partial independence in her daily activities.
Akiki Juliet	6	Batten Disease	Lebanon	2015	Spasticity disappeared and his grip returned.
Ross Taylor	32	SCA 2	Zimbabwe	2016	Spasticity disappeared and his grip returned.
Milan Ayan	8	Autism	Afghanistan	2016	Episodes of stumbling after waking disappeared.
Carl Stevens	57	Ischemic Optic Neuropathy	USA	2015	Able to speak in complete sentences more than ten words.
Mr. Brandon	19	Multiple Sclerosis	Australia	2015	Able to perceive light sources.
Mr. Osama	26	Amyotrophic Lateral Sclerosis	Ghana	2016	Able to walk at normal pace for a few km.
Md Rasheed	53	Traumatic Brain Injury	Pakistan	2015	Breathing improved; swallowing improved with less hiccup episodes.
David Robert Blair	33	SCA 1	Scotland	2015	Regained consciousness.

PATIENT TESTIMONIALS

PATIENT NAME	AGE	DISORDER	COUNTRY	YEAR OF TREATMENT	FOLLOW-UP FEEDBACK
Imran Khan	26	Traumatic Brain Injury	Bangladesh	2015	Increased balance and trunk strength.
Sana Naaz	2	Cerebral Palsy	Pakistan	2015	Dramatic increase in appetite.
Gabor Bocskai	19	Cerebral Palsy	Hungary	2015	Balance improved while sitting. Improvements in reading.
Ahmed	33	SCA 3	Afghanistan	2016	Choking during meals reduced.
Jessica	22	Traumatic Brain Injury	USA	2015	Tremors in the hands disappeared. Able to get out of the wheelchair unaided.
Jordan	13	Glucose Transporter Deficiency Syndrome	USA	2015	Speech and cognitive skills improved.
Sachin	43	ALS	India	2016	Balance improved while sitting.
Smith	59	Bulbar ALS	Australia	2016	Able to get out of the wheelchair unaided.
Kevin	37	Heart Disease	Australia	2015	Heart's ejection fraction improved from 20% to 50%.
Josephine Stramiello	3	Cerebral Palsy	Zimbabwe	2015	Overall muscle strength improved.
Shazad Ali	7	Cerebral Palsy	Iraq	2016	Balance and trunk strength improved.
Kymberly Graf	19	SCA 2	Canada	2016	Mobility and coordination improved considerably.
Michael	12	Autism	Australia	2016	Sensation improved.
Amy Lewis	2	Brain Injury	USA	2016	Improvements in awareness, responsiveness and sensory stimuli.
Sumaiya	9	Epilepsy	Pakistan	2016	Balance improved and climbed stairs unaided.
Gurmeet Singh	26	Friedrich's Ataxia	Australia	2016	Balance improved and increased sensation in the legs.
Lukas Nguyen	3	Traumatic Brain Injury	USA	2016	Muscle strength improved.
Maria	5	Autism	Romania	2016	Temper tantrums significantly reduced.
Mark Godzilla Yu	6	Autism	USA	2014-2016	Behavioural, language and social skills improved. Speech became clear and socially more amiable.
Raghav Sharma	12	Autism	India	2015	Able to dress himself and comb his hair.
Swati Verma	23	Ataxia	India	2016	Balance improved and climbed stairs without assistance.

PATIENT TESTIMONIALS

PATIENT NAME	AGE	DISORDER	COUNTRY	YEAR OF TREATMENT	FOLLOW-UP FEEDBACK
Maya Madura	7	Epilepsy	Hungary	2015-2016	Seizures had stopped and speech became better.
Mitchell Pacis	6	Autism	Australia	2015	Speech improved and started to utter single words.
Undisclosed	39	Glaucoma	South Africa	2016	Improvements bilaterally in visual acuity, visual field and VEP in post-treatment eye exam.
Nate Redman	17	SCA 7	USA	2016	Improvements in speech and balance.
Kevin	58	Huntington's Disease	USA	2016	Balance and mobility improved. Gave up cane for walking.
Paul Thomas Flynn	43	Hereditary Ataxia	USA	2014-2016	Improvements in balance and speech.
Rashid Ali	50	Multiple Sclerosis	Bangladesh	2014-2015	Convulsive tremors ceased. Gained some bladder control.
Undisclosed	12	Muscular Dystrophy	USA	2015	Increase in muscle strength.
Raghav Lakhota	21	Spinal Cord Injury	India	2014	First treatment—•vision improved considerably and could raise right arm completely. Second treatment—•no significant changes were seen.
Rajiv Saluja	52	Multiple Sclerosis	India	2016	First time—•100 % bladder control was achieved. Second time in 2012 — BP became normal and stopped taking his BP medication that he was taking since 1998.
Robert Frank Flynn	49	Hereditary Ataxia	USA	2015-2016	Able to stand in the shower without a support for an extended time.
Russ Kleve	58	FSHD Muscular Dystrophy	USA	2016	Walking and gait has improved. Falling has reduced.
Sachin Goel	28	Limb Girdle Muscular Dystrophy	India	2015	Improvements in shoulder muscle & improvement in stamina.
Susan Monica Glenn	41	Multiple Sclerosis	England	2014-2016	Balance improved and the convulsions reduced.
Timothy Graf	45	SCA2	USA	2015	Able to use the stairs without the help of the handrail.
Undisclosed	30	SMA3	Indonesia	2014-2016	Does not get asthmatic bronchitis during seasonal change.
Travis Ashton	18	Traumatic Brain Injury	USA	2015-2016	The major change was seen in the control of his mouth and drooling improved significantly.
Valerie Crowter	51	Hereditary Ataxia	Canada	2014-2016	A huge reduction in the frequency and severity of cramps in her legs.



PATIENT GALLERY



Stem Cell Care

India



<https://www.stemcellcareindia.com>



ABUL FAZAL ENCLAVE, JAMIA NAGAR,
NEW DELHI - 110025, INDIA



info@stemcellcareindia.com



International Patients : +91 8743024344,
Indian Patients : +91 7838223336



/StemCellCareIndia



+91 8743024344,
+91 7838223336



/StemCellCare



/StemCellCareIndia



/StemCellCareIndia



/company/stem-cell-care